



### PATIENT

Farley Barnett

### SPECIES

Canine

### BREED

Shepherd Mix

### SEX

Male Neutered

### AGE

11 years

### WEIGHT

29kgs

### INTERPRETED BY

Maggie Machen Lamy,  
DVM, DACVIM  
(Cardiology)

### IMAGING PERFORMED BY

Loetitia St-Jacques,  
LVT/RVT

### HOSPITAL NAME

Donner Truckee  
Veterinary Hospital

### REFERRING VET

Dr. Vannini

### INVOICE

29253

### DATE

2/27/23

### PRESENTING CLINICAL SIGNS

History: Acute collapse 2d ago. ER dx with pericardial effusion, removed 50ml blood. P has been doing well since.  
Abnormal PE/Chem/CBC/UA Results: Slightly abn hematocrit otherwise wnl.

### ECHOCARDIOGRAM FINDINGS

2D, m-mode, color flow and doppler imaging is available. Mild thickening of the anterior leaflet of the mitral valve with no obvious prolapse into the left atrial lumen. No mitral regurgitation with normal left atrial dimension. Normal LV diameter with adequate myocardial function. Normal LV wall thickness. Tricuspid valve appears mildly thickened with no TR. No obvious tumor in the RA or right auricle. Suspicious hypoechoic lesion associated with the right AV groove (see below; r/o tumor v benign tissue). The pulmonic and aortic valves are normal in morphology and mobility. Normal pulmonic outflow velocities; laminar flow. Scant pericardial effusion. Scant pleural effusion seen.

### CARDIAC CHART

CANINE CARDIAC PARAMETERS	MR VMAX (m/s)	TR VMAX (m/s)	LA/AO (Boon method)	LA/AO (Heart Base; Swe)	FS (%)	EF (%)	EPSS (cm)
NORMAL PARAMETER	4.5-5.5	<2.7	1.3	<1.6	28-40	40-100	<0.6
PATIENT	NA	NA	NM	1.1	28	55	0.7
CANINE CARDIAC PARAMETERS	HR (BPM)	AV VMAX (m/s)	PV MAX (m/s)	BODY WEIGHT (kg)	LA 2D short axis Base view (cm)	LVIDd Avg; 2D and m-mode short axis (cm)	LVIDs Avg; 2D and m-mode short axis (cm)
NORMAL PARAMETER	50-100	0.7-1.7	0.7-1.6	BELOW	BELOW	BELOW	BELOW
PATIENT	NM	1.4	1.1	30	2.9	3.7	2.7
*Normal chamber parameters expressed as a mean value (SD)				3	1.27 (5.3)	2.46 (2.46)	1.36 (5.5)
<b>BODY WEIGHT DEPENDENT PARAMETERS</b>				5	1.40 (4.5)	2.74 (5.2)	1.60 (4.7)
<i>*Note: All measurements based upon multi-modal images and methods. An average value is reported.</i>				10	1.50 (3.8)	3.27 (3.5)	2.06 (3.1)
				15	1.83 (2.0)	3.71 (2.4)	2.43 (2.1)
				20	2.02 (1.9)	4.14 (2.2)	2.80 (2.0)
				25	2.18 (2.4)	4.48 (2.9)	3.10 (2.5)
				30	2.33 (3.3)	4.83 (3.9)	3.39 (3.4)
				35	2.48 (4.3)	5.17 (5.0)	3.69 (4.5)
				40	2.62 (5.2)	5.48 (6.1)	3.96 (5.4)
				50	2.88 (7.1)	6.07 (8.3)	4.46 (7.4)

Adapted from June Boon, Veterinary Echocardiography, 1998  
Rishniw M and Hollis NE, J Vet Intern Med 2000; 14:429-435  
Hansson et al, Vet Rad and Ultrasound 2002  
Bonagura et al. Echocardiography: principles of interpretation, Vet Clin North Am 15:1177, 1995

### INTERPRETATION OF THE FINDINGS & FURTHER RECOMMENDATIONS

The 2 most common causes of hemorrhagic pericardial effusion in an older large breed dog without structural disease are idiopathic and neoplastic. Less commonly, pericarditis (an inflammatory condition) or a bleeding disorder should also be considered. Idiopathic by definition means that a cause cannot be found. If diagnosed (a rule out diagnosis), the long-term prognosis with idiopathic effusion has the potential to be good.

Regarding neoplasia, the most common types of cardiac cancer-causing pericardial effusion include hemangiosarcoma (HSA), chemodectoma, or mesothelioma. The prognosis varies a great



Portable Animal Western Sonography, Inc.

IMAGING PERFORMED BY

pawsonography@gmail.com 530-786-8340

**PATIENT**

Farley Barnett

deal depending on the underlying type of cancer. In a senior Akita, HSA should be considered above all other differentials, as this is the most common cause. Cardiac HSA carries a poor to grave prognosis, with a mean survival time of 3-6 months.

**SPECIES**

Canine

Based on the findings of today's echocardiogram, there is suspicion for a tumor in the right AV groove. This is not definitive; however, suspicion is high. Ultrasound is quite insensitive for small masses (particularly in the absence of active effusion), and it is important to note that there may be a definitive mass not identified here. A reevaluation is recommended in the next 1-2 months, as often small masses will become apparent in that period of time. Prognosis is guarded, and any dog with effusion carries risk for development of malignant arrhythmias and sudden death at home.

**BREED**

Shepherd Mix

**SEX**

Male Neutered

Further evaluation may also help shed light on a definitive diagnosis. Submission of the effusion for cytology can yield a diagnosis in rare cases, and often the result is inconclusive. If the abdominal ultrasound shows any splenic lesions, HSA is highly likely to be the cardiac diagnosis. Advanced imaging with an attending Cardiologist can be considered, as well as discussion of a thoracic CT/MR to screen the external surface of the heart.

**AGE**

11 years

Regardless of underlying cause, it is impossible to predict if and when pericardial effusion will recur/increase and potentially cause clinical signs. Some patients with idiopathic effusion need to be tapped between 1 and 3 times then never again. Other patients may experience frequent recurrence with either HSA or idiopathic disease. If the effusion reoccurs frequently and no malignancy remains identified, a surgical procedure called a pericardectomy can be discussed. Finally, dogs with effusion are at risk for malignant ventricular arrhythmias, and a baseline ECG is recommended. Sudden death is always a possibility in these cases unfortunately.

**WEIGHT**

29kgs

**INTERPRETED BY**

Maggie Machen Lamy,  
DVM, DACVIM  
(Cardiology)

No cardiac medications are clearly indicated at this time. Over the counter herbal supplement Yunnan Baiyao (aka Yunnan Paiyao) may help decrease risk of bleeding, however true benefit is speculative (1 capsule PO BID). Please monitor at home for signs of worsening pericardial effusion including pale gums, difficulty breathing, lethargy/collapse, exercise intolerance, abdominal distention, vomiting, and/or inappetance. If you notice any of these symptoms, patient should be evaluated immediately by a veterinarian.

**IMAGING PERFORMED BY**

Loetitia St-Jacques,  
LVT/RVT

Recommend a recheck echocardiogram in 2 months to reassess the surface of the heart and screen for recurrent effusion, sooner if any recurrence of clinical signs. If acute PCE occurs again, if possible, recommend imaging prior to removal for increased sensitivity.

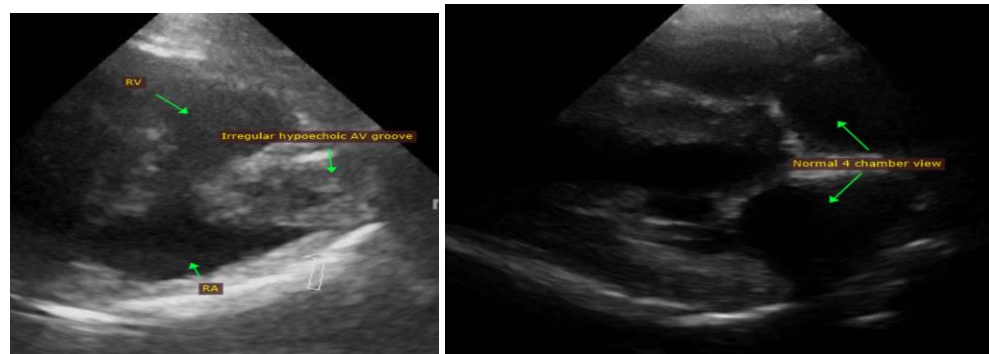
**HOSPITAL NAME**

Donner Truckee  
Veterinary Hospital

**IMAGES**

**REFERRING VET**

Dr. Vannini



**INVOICE**

29253

**DATE**

2/27/23



**PATIENT**

Farley Barnett

**SPECIES**

Canine

**BREED**

Shepherd Mix

**SEX**

Male Neutered

**AGE**

11 years

**WEIGHT**

29kgs

**INTERPRETED BY**

Maggie Machen Lamy,  
DVM, DACVIM  
(Cardiology)

**IMAGING  
PERFORMED BY**

Loetitia St-Jacques,  
LVT/RVT

**HOSPITAL NAME**

Donner Truckee  
Veterinary Hospital

**REFERRING VET**

Dr. Vannini

**INVOICE**

29253

**DATE**

2/27/23

The information and recommendations provided are based on the images presented by the referring veterinarian. No evaluation can be communicated regarding pathology that was not visible in the image/video clips provided.

Thank you for this referral. If the clinical or image interpretation does not parallel your findings or if I can be of any further assistance, please contact me.

Maggie Machen Lamy, DVM  
Diplomate of the American College of Veterinary Internal Medicine (Cardiology)  
info@sonopath.com